

Case Report

Synchronous Parathyroid Carcinoma and Multifocal Papillary Thyroid Carcinoma: A Case Report

Fatih Kuzu,¹ Ahmet Cinkaya,² Mehmet Fatih Ekici,³ Hilmi Kodaz,⁴ Aysenur Deger⁵

¹Department of Endocrinology, Evliya Celebi Training and Research Hospital, Kutahya, Turkey

²Department of Radiation Oncology, Dumlupinar University Faculty of Medicine, Kutahya, Turkey

³Department of General Surgery, Evliya Celebi Training and Research Hospital, Kutahya, Turkey

⁴Department of Medical Oncology, Acıbadem Eskisehir Hospital, Eskisehir, Turkey

⁵Department of Pathology, Dumlupinar University Faculty of Medicine, Kutahya, Turkey

Abstract

The coexistence of parathyroid carcinoma and thyroid carcinoma is extremely rare. Presently described is a case with multinodular goiter and parathyroid adenoma pre-diagnosis for which operation was planned that was postoperatively diagnosed with multifocal papillary thyroid carcinoma accompanying parathyroid carcinoma. A review of the current literature is also provided.

Keywords: Multinodular goiter, papillary thyroid carcinoma, parathyroid adenoma, parathyroid carcinoma

Cite This Article: Kuzu F, Cinkaya A, Ekici M, Kodaz H, Deger A. Synchronous Parathyroid Carcinoma and Multifocal Papillary Thyroid Carcinoma: A Case Report. *EJMO*. 2017; 1(1): 49-52

Parathyroid carcinoma (PC) is a rare endocrine tumor and constitutes less than 1% of all cases of primary hyperparathyroidism (PHPT).^[1] It is difficult to diagnose PC preoperatively, as its clinical features are similar to PHPT. Severe end-organ damage, including symptoms related to hypercalcemia, renal insufficiency, bone diseases, cardiac arrhythmia, and neurocognitive dysfunction may be observed. PC has a more aggressive progress compared with clinical PHPT, and may emerge with a mass in the neck. On the other hand, some patients show no symptoms. Although it is very rarely observed, patients with nonfunctional PC may also have normal calcium and parathormone (PTH) levels.^[2]

The coexistence of PHPT with thyroid disease is not common. Thyroid pathology has been reported in 15% to 70% of patients with PHPT. The coexistence of PHPT with medullary thyroid cancer is common in multiple endocrine

neoplasia type 2 (MEN2, Sipple syndrome). In contrast, the coexistence of PHPT and non-medullary thyroid carcinoma is very rare (1–2%). The coexistence of PC and thyroid carcinoma is extremely rare. Only 12 cases of coexistence of PC and non-medullary thyroid carcinoma were returned in PubMed and Medline searches.

Case Report

A 52-year-old female patient following-up diagnosis of osteoporosis in the physical therapy and rehabilitation clinic was referred to the endocrinology clinic due to hypercalcemia found in routine examinations. The patient had received nonsteroidal anti-inflammatory and muscle relaxant treatment for muscle aches and cramps during follow-up for osteoporosis. Examination of the patient's history revealed diabetes mellitus type 2, hypertension, multinodular goiter, peptic ulcer, and depression, and she was receiv-

Address for correspondence: Fatih Kuzu, MD. Dumlupinar Universitesi, Evliya Celebi Egitim ve Arastirma Hastanesi, Endokrinoloji Klinigi, Kutahya, Turkey

Phone: +90 530 826 62 04 **E-mail:** drfkuzu@hotmail.com

Submitted Date: May 22, 2017 **Accepted Date:** July 03, 2017 **Available Online Date:** August 03, 2017

©Copyright 2017 by Eurasian Journal of Medicine and Oncology - Available online at www.ejmo.org



ing medical treatment in line with these diagnoses. There was no known thyroid or parathyroid cancer in her family history. Physical examination results were weight of 76 kg, height of 163 cm, blood pressure of 135/85 mmHg, thyroid stage 1b, and with palpation it was found that she had nodules of moderate hardness, approximately 1-1.5 cm in size in both lobes.

Serum biochemical evaluation values were alkaline phosphatase: 74 U/L, calcium: 11.4 mg/dL, phosphorus: 2.6 mg/dL, and 25-hydroxy vitamin D: 11.8 ng/mL. Full blood count was normal. Hormonal evaluation values were thyroid-stimulating hormone: 0.69 uIU/mL, free thyroxine: 0.69 ng/dL and PTH: 208 pg/mL. The patient's bone scintigraphy was compatible with osteoporosis, and urinary sonographic imaging was assessed as normal.

Follow-up sonographic imaging based on diagnosis of multinodular goiter and hypothyroidism revealed heterogeneous, hypoechoic, and isoechoic nodules, the largest of which in the right lobe was 15 × 9 × 8 mm and 17 × 10 × 6 mm in the left lobe. Some nodules had faint contour and some included coarse calcification. In addition, a hypoechoic lesion, thought to be parathyroid adenoma, 18 × 10 × 5 mm in size was detected adjacent to the right lower lobe of the thyroid and extending to the posterior carotid artery. Activity involvement compatible with parathyroid adenoma in the thyroid area and mediastinum were not detected in the scintigraphic evaluation of the lesion. Result of fine needle aspiration (FNA) biopsy of thyroid nodules was benign. PTH level was 3482 pg/mL after PTH washout of the suspected parathyroid adenoma lesion.

The patient was referred to the general surgery clinic with a recommendation of total thyroidectomy and parathyroid surgery, since thyroid cancers are typically asymptomatic and can easily be overlooked in patients with hyperparathyroidism. PC was considered, since the parathyroid-originated lesion demonstrated invasion into the common carotid artery during surgery accompanied by intraoperative gamma probe application. The operation concluded with en bloc resection and right lobectomy because the PC was suspicious in frozen sections. Pathology report of the histomorphological and histochemical findings was PC. The nodule on the right thyroid lobe was reported as a classic variant papillary microcarcinoma. Nodular hyperplasia and lymphocytic infiltration were detected in the thyroid tissue outside the tumor (Figures 1–3). PTH, phosphorus, and calcium levels were found to be 41 pg/mL, 3 mg/dL, and 8.2 mg/dL, respectively, after the surgery. Oral calcium and vitamin D3 treatment was planned. Thoracic and abdominal tomographic images and bone scintigraphy of the patient were normal.

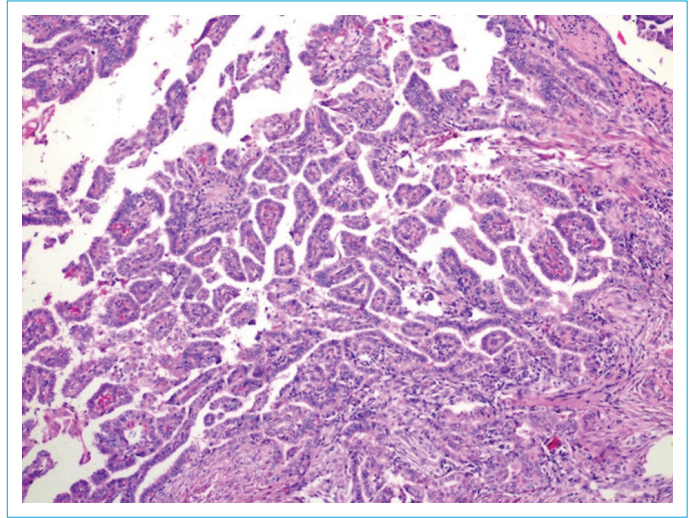


Figure 1. Thyroid papillary carcinoma. Hematoxylin and eosin x100.

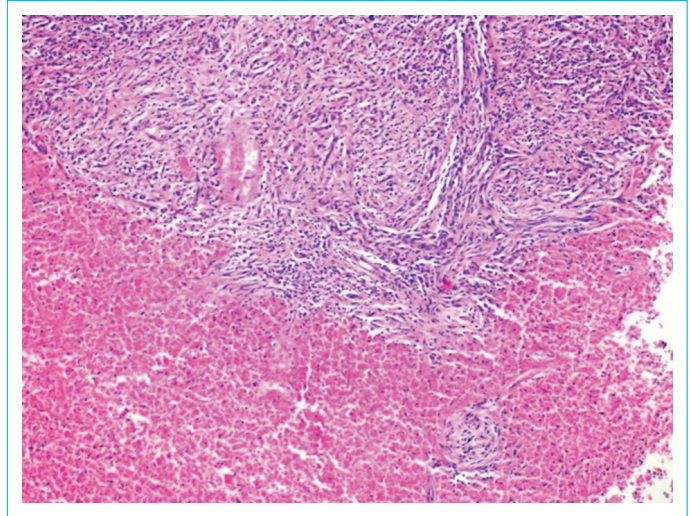


Figure 2. Parathyroid carcinoma and common area of necrosis with eosinophilic features. Hematoxylin and eosin x100.

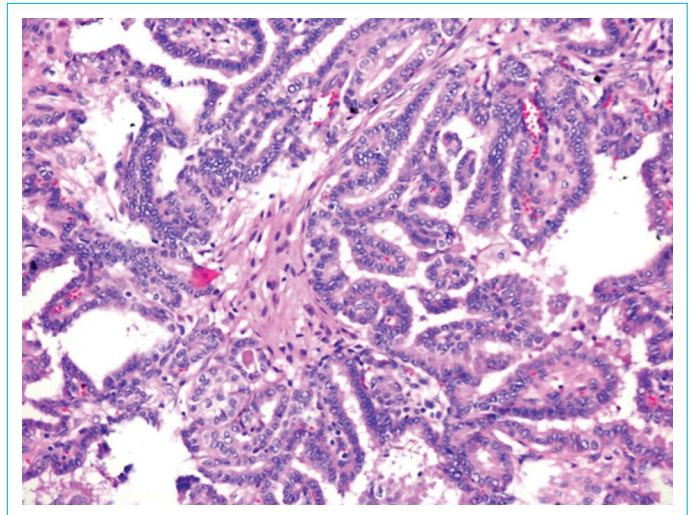


Figure 3. Papillary carcinoma and tumor cells with a frosted glass appearance. Hematoxylin and eosin x400.

Complementary thyroidectomy was performed 6 weeks later. The pathology was reported as papillary thyroid cancer. The tumor was 10 × 8 × 5 mm in size.

The patient was treated with 100 mL of radioactive iodine for papillary thyroid carcinoma. As the patient had a normocalcemic process, follow-up of 1-thyroxine treatment in suppressive dose was initiated.

Discussion

PC pathogenesis is not fully known. Although it is generally seen as a sporadic disease, it can also emerge as part of a genetic syndrome. Hyperparathyroidism jaw tumor syndrome (HPT-JT), MEN1, MEN2 and isolated familial hyperparathyroidism are genetic syndromes reported to be associated with PC. The mutations of the MEN1 gene seen in MEN1 syndrome may be responsible. As a result of the MEN1 gene mutation, the inhibitory effect of transforming growth factor beta/SMAD3 on parathyroid cell proliferation is eliminated.^[3, 4] Mutations in RET proto oncogenes are found in MEN2 syndrome. HPT-JT is associated with an onco suppressor parafibromin (HRPT2/CDC73) gene mutation. Abnormal expression of microRNAs (miRNAs) also has an important role in the development and progression of PC.^[5, 6] Genetic syndromes are the only precisely defined risk factor. PC has been reported previously in cases with radiation exposure to the head and neck region, and in patients with secondary or tertiary hyperparathyroidism due to chronic renal insufficiency.^[7, 8] Among the risk factors, the only common cause of parathyroid and thyroid carcinomas is radiation exposure to the head and neck region. In our case, there was no such radiation exposure and there were no other risk factors.

A minimum of 2 imaging methods is necessary to localize the lesion. Technetium-99m sestamibi scan and neck ultrasonography combination is the most often used. However, though the cited images are helpful in localization, they are inadequate to detect the potential of malignancy. Size larger than 3 cm on sonography and presence of lobule with non-homogenous pattern, significant hypoechoic and degenerative changes, calcification, and irregular halo properties increase PC suspicion. Parathyroid adenomas are smaller, homogeneous, smooth, confined lesions. Neck, mediastinum, chest, and abdomen computed tomography (CT) and magnetic resonance imaging are important in terms of recurrence and metastasis. Thin-section neck CT is helpful for lesion localization if sestamibi scan is negative. In our case, the sestamibi scan was negative. PTH washout was performed with FNA of the lesion extending to the carotid artery posterior from the posterior thyroid right lower lobe. The PTH value in the washout fluid was 3482 pg/

mL. FNA biopsy process performed on patients who are thought to have PC carries the risk of tumor seeding. The PTH washout procedure can be used to distinguish suspicious parathyroid lesions that have negative sestamibi scan but detected on sonographic and CT scans from negative thyroid lesions and metastatic/non-metastatic lymph nodes.^[9]

Although a relationship between hyperparathyroidism and well differentiated thyroid carcinoma is rare, it has been reported in numerous studies. A total of 824 primary, secondary, and tertiary hyperparathyroidism patients who underwent minimal lobectomy were evaluated in a retrospective study conducted by Burmeister et al. Thyroid carcinoma was detected in 18 (2.6%) of 700 patients with PHPT, and 22 patients were found to have thyroid carcinoma among total of 824 patients. One of the 22 patients was diagnosed with follicular carcinoma, while 21 patients were diagnosed with papillary carcinoma. Thyroid carcinoma was not found in any of the 9 patients with PC in this retrospective study.^[10, 11] Nodular thyroid disease was detected in 102 of the 200 patients for whom surgery was planned with diagnosis of hyperparathyroidism in the study reported by Morita et al. Thyroid cancer was identified in 12 patients (6%) after surgery. All cases had thyroid papillary cancer, with 1 case of follicular variant. The incidence of thyroid cancer in hyperparathyroidism patients who underwent surgery in several series varied between 2.2% and 17.6%.^[12]

Minimally invasive procedures have emerged for parathyroid adenoma in the last decade; however, detailed sonographic imaging of the thyroid must be performed preoperatively when a minimally invasive procedure is planned for primary hyperparathyroidism. The most suitable patient for a minimally invasive intervention is the patient group without accompanying nodular thyroid disease. If concomitant nodular thyroid disease is detected, FNA biopsy should be performed on appropriate nodules and a re-evaluation made based on the biopsy results. If there are no suspicions of malignancy in the sonographic evaluation of the nodule, and if the FNA result is benign, minimally invasive approach should be considered. But if the sonographic image is suspicious even though the FNA result is Bethesda System 3-4-5-6 or FNA is benign, total/subtotal thyroidectomy should be added to the parathyroid surgery. Although the FNA results in our case were benign, thyroidectomy was performed due to suspicious sonographic findings.

Many PC cases present with a hypercalcemic crisis table, known as parathyrotoxic crisis. It may also present with either normocalcemia or moderate hypercalcemia. In most cases, presence of calcium level higher than 14 mg/dL,

presence of PTH at least 3 times higher than the upper limit of normal, presence of a palpable mass in the neck, neck pain, hoarseness, visualization of invasion to surrounding tissues, presence of severe level of bone or renal involvement, or presence of family history are risk factors that inform the clinician regarding the likelihood of PC.^[1, 13] Detection of locally invasive and/or regional metastasis intraoperatively by the surgeon is also an important risk factor for PC.^[13] Surgery was planned in our case with idea of parathyroid adenoma biochemically and hormonally prior to surgery. Invasion of the common carotid artery and the surrounding tissues was detected intraoperatively, and the surgery was completed with en bloc resection and ipsilateral hemithyroidectomy, considering it PC. Pathology results indicated that the parathyroid-originated lesion was indeed PC and that the nodular lesion in the right thyroid lobe was papillary thyroid carcinoma. Complementary thyroidectomy was performed because there were suspicious nodular lesions in the left thyroid lobe, though the patient had normal calcium and PTH values. A nodule in the left thyroid lobe was determined to be papillary thyroid carcinoma. The patient was diagnosed with multifocal papillary thyroid carcinoma and high dose radioactive iodine treatment was pursued.

The points that need to be emphasized are as follows:

- PC is hormone-active and its symptoms are severe. It may be present with moderate hypercalcemia or normocalcemic patient, as in our case, although it is usually found with apparent hypercalcemia. Diagnosis is especially difficult prior to surgery in these cases.
- As in our case, the Technetium-99 m sestamibi scan may be negative. In these cases, detailed neck ultrasonography or computerized tomography can be useful for localization. If laboratory findings and clinical and imaging methods suggest parathyroid adenoma, PTH-washout may be planned for the suspicious lesion for precise localization before the surgery. However, when PC is suspected, there is a risk of tumor seeding, and the procedure should not be performed unless it is necessary.
- If there is coexistence of PC and multinodular goiter, the appropriate approach would be en bloc resection and total thyroidectomy.

Disclosures

Peer-review: Externally peer-reviewed.

Conflict of Interest: None declared.

References

1. Cetani F, Pardi E, Marcocci C. Update on parathyroid carcinoma. *J Endocrinol Invest* 2016;39:595–606. [\[CrossRef\]](#)
2. Wang J, Gao L, Song C, Xie L. Incidence of metastases from 524 patients with papillary thyroid carcinoma in cervical lymph nodes posterior to the sternoclavicular joint (level VIa): Relevance for endoscopic thyroidectomy. *Surgery* 2016;159:1557–64. [\[CrossRef\]](#)
3. Sharretts JM, Simonds WF. Clinical and molecular genetics of parathyroid neoplasms. *Best Pract Res Clin Endocrinol Metab* 2010;24:491–502. [\[CrossRef\]](#)
4. Marx SJ, Simonds WF, Agarwal SK, Burns AL, Weinstein LS, Cochran C, et al. Hyperparathyroidism in hereditary syndromes: special expressions and special managements. *J Bone Miner Res* 2002;17 Suppl 2:N37–43.
5. Verdelli C, Forno I, Vaira V, Corbetta S. MicroRNA deregulation in parathyroid tumours suggests an embryonic signature. *J Endocrinol Invest* 2015;38:383–8. [\[CrossRef\]](#)
6. Corbetta S, Vaira V, Guarnieri V, Scillitani A, Eller-Vainicher C, Ferrero S, et al. Differential expression of microRNAs in human parathyroid carcinomas compared with normal parathyroid tissue. *Endocr Relat Cancer* 2010;17:135–46. [\[CrossRef\]](#)
7. Shane E. Clinical review 122: Parathyroid carcinoma. *J Clin Endocrinol Metab* 2001;86:485–93. [\[CrossRef\]](#)
8. Khan MW, Worcester EM, Straus FH 2nd, Khan S, Staszak V, Kaplan EL. Parathyroid carcinoma in secondary and tertiary hyperparathyroidism. *J Am Coll Surg* 2004;199:312–9. [\[CrossRef\]](#)
9. Trimboli P, D'Aurizio F, Tozzoli R, Giovanella L. Measurement of thyroglobulin, calcitonin, and PTH in FNA washout fluids. *Clin Chem Lab Med* 2017;55:914–25. [\[CrossRef\]](#)
10. Burmeister LA, Sandberg M, Carty SE, Watson CG. Thyroid carcinoma found at parathyroidectomy: association with primary, secondary, and tertiary hyperparathyroidism. *Cancer* 1997;79:1611–6. [\[CrossRef\]](#)
11. Iakovou IP, Konstantinidis IE, Chrisoulidou AI, Doumas AS. Synchronous parathyroid adenoma and thyroid papillary carcinoma: a case report. *Cases J* 2009;2:9121. [\[CrossRef\]](#)
12. Morita SY, Somervell H, Umbricht CB, Dackiw AP, Zeiger MA. Evaluation for concomitant thyroid nodules and primary hyperparathyroidism in patients undergoing parathyroidectomy or thyroidectomy. *Surgery* 2008;144:862–6. [\[CrossRef\]](#)
13. Duan K, Mete Ö. Parathyroid Carcinoma: Diagnosis and Clinical Implications. *Turk Patoloji Derg* 2015;31 Suppl 1:80–97.